

Unusual Migration of an Intrauterine Contraceptive Device: A Silent Journey to the Appendix – A Case Report

Usman Shah Bukhari¹, Naveed Ahmed², Saqlain Anwar², Muhammad Raza Sarfraz^{3*}, Urooj Fatima³, Roha Bilal², Muhammad Saad Saeed³, Hafiz Muhammad Ahmad³, Hamid Mehmood⁴ and Ahmer Riaz⁵

¹Department of Surgery, Combined Military Hospital, Rawalpindi, Pakistan

²Department of Surgery, Pakistan Navy Station Shifa, Karachi, Pakistan

³Allied Hospital, Faisalabad Medical University, Faisalabad, Pakistan

⁴HITEC Institute of Medical Sciences, Taxila, Pakistan

⁵Services Institute of Medical Sciences, Lahore, Pakistan

Abstract

Intrauterine devices (IUCDs) are commonly used for contraception, but can rarely migrate and cause complications. Although migration into the peritoneal cavity has been reported, migration into the appendix leading to appendicitis and perforation is sporadic. We report the case of a 32-year-old woman who presented with acute abdominal pain due to perforated appendicitis caused by migration of an IUCD into the appendix. Imaging revealed peritonitis and free pelvic fluid, prompting an emergency laparotomy. Intraoperatively, the IUCD was found embedded in the perforated appendix and adherent to the right adnexa. Interestingly, no uterine perforation was observed, suggesting delayed secondary perforation and silent migration over time. An appendectomy with IUCD retrieval was performed, followed by an uneventful recovery. This case highlights an infrequent but essential complication of IUCD migration. It underscores the importance of timely diagnosis, appropriate imaging, and urgent surgical intervention to prevent severe morbidity in cases of IUCD-associated complications.

Keywords: *Appendicitis, intrauterine contraceptive devices, spontaneous migration, laparotomy.*

INTRODUCTION

Intrauterine contraceptive devices (IUCDs) have been in use worldwide since 1965 [1]. Numerous case reports have described complications associated with IUCDs. Perforation and migration to other organs are among the rarest but potentially life-threatening complications [2]. These perforations are often linked to insertions performed during the early postpartum period or during lactational amenorrhea. The success and safety of insertion are closely related to the clinician's skill [3]. A few reports have described the rare occurrence of transmigration to the appendix, resulting in inflammation and requiring either laparoscopic or open appendectomy [2, 4]. In such cases, symptoms may be delayed due to chronic inflammation caused by the copper content of the IUCD [2]. We present a case of a young woman who arrived at the emergency department with symptoms suggestive of acute appendicitis. She was provisionally diagnosed and treated; however, her symptoms persisted, and the decision for surgery was subsequently made.

CASE REPORT

Presentation

A 32-year-old married woman presented to the emergency department with a three-day history of abdominal pain. The pain was predominantly localized to the right iliac fossa and hypogastrum, with abrupt onset, moderate

intensity, and a gripping character. It was associated with burning micturition. She also reported nausea, vomiting, anorexia, and fever. There was no history of constipation or diarrhea. The patient had initially presented to a local clinic with similar complaints, where she was admitted and given prophylactic analgesics and antibiotics. Her last menstrual period was two days before presentation. She had a history of IUCD insertion three years earlier, which had not been removed. The patient had not attended any gynecological follow-up visits since IUCD insertion three years earlier, as she remained asymptomatic until the current episode. She was not diabetic or hypertensive, had no previous surgical history, and was a non-smoker. Her family and socioeconomic history were unremarkable.

Clinical Findings

On inspection, a young female of heavy build was lying on the bed in an irate condition, with a pulse rate of 120 beats/min, B.P. of 105/64 mmHg, and respiratory rate of 24 breaths/min. She was afebrile, with an oxygen saturation of 96% on room air. Her abdominal examination was positive for a distended, rigid abdomen with generalized tenderness. No visceromegaly was appreciated, and bowel sounds were heard. A digital rectal examination found soft and scanty stools in the rectum, which were not blood-stained and had no palpable mass.

Diagnostic Assessment

Early lab tests revealed neutrophilia and increased total white blood cell levels of 16500 cells/mm³. Additionally,

*Corresponding author: Muhammad Raza Sarfraz, Allied Hospital, Faisalabad Medical University, Faisalabad, Pakistan, Email: mrazasarfraz@outlook.com
Received: May 05, 2025; Revised: August 12, 2025; Accepted: August 19, 2025
DOI: <https://doi.org/10.37184/jlnh.2959-1805.4.1>

C-Reactive Protein (CRP) increased. Serum urea, creatinine, electrolyte levels, and liver function tests, however, were all within acceptable limits.

The X-ray of her chest showed nothing unusual. An abdominal ultrasound revealed a dilated blind-ending peristaltic loop of intestine in the right iliac fossa, free fluid in the pelvis, and fat stranding in the same area. No foreign body was visualized on the ultrasound. The Alvarado Score was 8/10, indicating a high likelihood of appendiceal perforation based on the patient's clinical presentation and laboratory findings (Table 1). An immediate surgical consultation was obtained, and a diagnosis of sepsis secondary to peritonitis from a perforated appendix was made.

Table 1: Total Alvarado score calculation.

Alvarado Score Component	Points	Findings in the Case
Right lower quadrant tenderness	2	Present
Leukocytosis >10,000/ μ L	2	Present
Migratory pain	0	Absent
Anorexia	1	Present
Nausea/vomiting	1	Present
Rebound tenderness	1	Present
Fever >37.5°C	1	Present
Neutrophilia >75%	1	Present
Total Score	8/10	Suggestive of appendicitis

Therapeutic Intervention

The patient was resuscitated with intravenous fluids, broad-spectrum antibiotics, and analgesics. A nasogastric tube and a Foley catheter were inserted, and input–output monitoring was initiated. Under general anesthesia, a lower midline laparotomy was performed. The abdomen was opened in layers, revealing approximately 300 ml of purulent fluid in the peritoneal cavity, which was drained (Fig. 1A).

The base of the appendix was identified, and a perforation was noted in its mid-portion, through which a small plastic fragment was protruding. The remainder of the appendix descended into the pelvis and was adherent to the right ovary and fallopian tube. Dissection revealed a twisted object within the appendix, which was identified as an IUCD (Fig. 1B). The right fallopian tube and ovary appeared mildly inflamed. At the same time, the uterus was grossly normal with no identifiable perforation site. This likely indicates that a uterine wall breach had occurred a considerable time earlier, allowing for healing and fibrosis. The IUCD may have migrated silently due to chronic inflammation, myometrial contractions, or

malposition, gradually eroding through the uterine wall and into the appendix (Fig. 1C).

An appendectomy was performed, and the abdominal cavity was irrigated thoroughly with warm saline. The incision was closed in layers, and a drain was placed. The patient was transferred to the intensive care unit (ICU) for post-operative monitoring.

Recovery was uneventful. The patient was mobilized on the first post-operative day, with incentive spirometry and chest physiotherapy initiated. By the third post-operative day, bowel sounds had returned, allowing removal of the nasogastric tube and initiation of oral fluids. She continued to improve and was discharged on the fourth post-operative day.

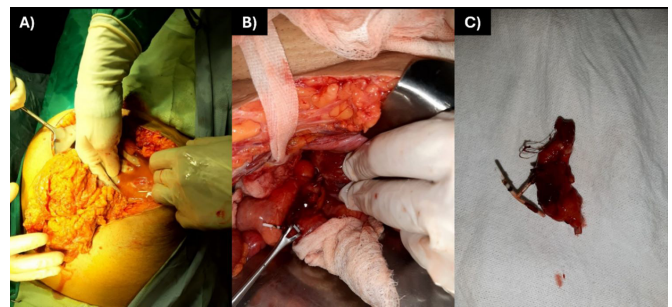


Fig. (1): A: Free fluid in the peritoneal cavity and fat stranding, B: Intrauterine contraceptive devices (IUCD) twisted around the appendix (shown by the green arrow), and C: Appendectomy specimen containing the migrated IUCD.

Histopathology

Histopathological examination of the excised appendix revealed acute suppurative appendicitis characterized by transmural neutrophilic infiltration and mucosal ulceration. The presence of multinucleated giant cells, histiocytes, and granuloma formation indicated a chronic inflammatory response to the foreign material.

Follow-up and Outcomes

At the 1-week follow-up, the patient had no active complaints, and the baseline profile was within normal limits, indicating no post-operative complications. An abdominal ultrasound was done, which was unremarkable. The patient's overall condition indicated a good surgical outcome.

DISCUSSION

Uterine perforation is a serious complication of IUCD use, and subsequent device migration may result in involvement of adjacent organs, including the appendix [5]. Globally, over 150 million women use IUCDs, with the majority residing in developing countries. Existing studies report that IUCD perforations occur in approximately 0.3-2.6 cases per 1,000 insertions [6, 7]. While common causes of appendicitis include

infections, tumors, fecaliths, foreign bodies, intestinal parasites, and lymphoid hyperplasia [8], rare etiologies, such as transmigration of an IUCD to the appendix, have also been documented [2].

Several published reports describe cases of IUCD migration to the appendix, similar to the present case. One study reported an IUCD-induced acute appendicitis successfully managed *via* laparoscopic appendectomy [9]. In our case, migration is likely to result from the gradual erosion of the uterine wall following IUCD insertion. Previous studies have suggested that symptoms may be delayed due to chronic inflammation triggered by the copper content of IUCD [3]. Another report highlighted the pronounced inflammatory response associated with such perforations and emphasized the need for prompt surgical intervention [6]. Unlike cases where uterine perforation occurs shortly after insertion and is promptly identified, our patient exhibited no early warning signs. This underscores the importance of routine post-insertion follow-up and imaging, such as ultrasonography, to detect early displacement and prevent complications. Although our clinical presentation and operative findings align with those reported in the literature, this case reinforces the need for vigilant monitoring and timely evaluation to mitigate the risks of IUCD migration.

IUCDs remain a reliable, cost-effective method of long-term contraception with low failure rates. Nevertheless, complications including bleeding, infection, ectopic pregnancy, and uterine perforation can occur. Uterine perforation, though rare, remains one of the most serious IUCD-related complications [10]. In our patient, the delayed onset of symptoms supports the likelihood of secondary migration [11]. We infer that the perforation was the result of gradual erosion through the uterine wall, likely beginning soon after insertion. The absence of fecalith impaction in the appendix suggests that chronic inflammation induced by the copper-containing IUCD was the primary precipitating factor for acute appendicitis in this case.

CONCLUSION

This case is a valuable contribution to the existing literature, providing insight into a rare complication of IUCD migration. It emphasizes the necessity of long-term IUCD surveillance, highlights a diagnostic challenge, and serves as an educational moment for surgeons and gynecologists on possible IUCD insertion complications. Proper post-insertion follow-up and routine self-checks of IUCDs play a crucial role in early identification of displacement and in preventing

potentially dangerous complications. Early surgical correction remains the curative measure in such circumstances, as evidenced by this patient's positive outcome.

CONSENT FOR PUBLICATION

Written informed consent was taken from the patient authorizing the publication of this case report and/or any accompanying images.

CONFLICT OF INTEREST

The authors declare no conflict of interest.

ACKNOWLEDGEMENTS

Declared none.

AUTHORS' CONTRIBUTION

USB and NA conceived the study and contributed to its design. SA, RB, and AR were involved in data acquisition and literature review. MRS supervised the project and contributed to the conceptualization of the study. UF contributed to case documentation and clinical interpretation. MRS, SA, MSS, and HMA drafted the initial manuscript. HM contributed to the critical revision of the manuscript for important intellectual content. All authors read the final version and approved the manuscript for publication.

GENERATIVE AI AND AI-ASSISTED TECHNOLOGIES IN THE WRITING PROCESS

During the preparation of this work, the author(s) used Claude AI (Sonnet 4.6) solely for language suggestions and minor proofreading in selected parts of the manuscript. It was not used for data analysis, interpretation of results, or any scientific or intellectual contribution to this work. The author(s) have thoroughly reviewed and edited all AI-assisted content and take full responsibility for the accuracy, integrity, and originality of the published work.

REFERENCES

1. Zakin D, Stern WZ, Rosenblatt R. Complete and partial uterine perforation and embedding following insertion of intrauterine devices. I. Classification, complications, mechanism, incidence, and missing string. *Obstet Gynecol Surv* 1981; 36(7): 335-53. DOI: <https://doi.org/10.1097/00006254-198107000-00001> PMID: 7029368
2. Chang HM, Chen TW, Hsieh CB, Chen CJ, Yu JC, Liu YC, et al. Intrauterine contraceptive device appendicitis: a case report. *World J Gastroenterol* 2005; 11(34): 5414-5. DOI: <https://doi.org/10.3748/wjg.v11.i34.5414> PMID: 16149161
3. Andersson K, Ryde-Blomqvist E, Lindell K, Odland V, Milsom I. Perforations with intrauterine devices: report from a Swedish survey. *Contraception* 1998; 57(4): 251-5. DOI: <https://doi.org/10.1016/s0010-7824%2898%2900029-8> PMID: 9649917

4. Sebai A, Elaifia R, Atri S, Hammami M, Haddad A, Kacem JM. Intrauterine device migration resulting in acute appendicitis: a case report. *Int J Surg Case Rep* 2024; 117: 109515. DOI: <https://doi.org/10.1016/j.ijscr.2024.109515> PMID: 38471208
5. Khan G, Khan A, Khan H, Faheem H, Shaukat M. From contraception to complication: Copper-T intrauterine contraceptive device migration leading to foreign body appendicitis. *J Perioper Pract* 2025: 17504589251355395. DOI: <https://doi.org/10.1177/17504589251355395>.
6. Verstraeten V, Vossaert K, Van den Bosch T. Migration of intra-uterine devices. *Open Access J Contracept* 2024; 15; 41-7. DOI: <https://doi.org/10.2147/OAJC.S458156> PMID: 38495451
7. Pourhoseini SA, Hafizi L, Jafari M. The migration of an intrauterine device in the bladder of an asymptomatic woman: a case report. *J Reprod Infertil* 2024; 25(3): 238-41. DOI: <https://doi.org/10.18502/jri.v25i3.17019> PMID: 39830318
8. Khai NX, Dung NV, Tien TD, Hai DM, Khanh NN, Van Duy T, *et al.* Acute appendicitis induced by bone fragment ingestion: a pediatrics case report. *Radiol Case Rep* 2024; 19(11): 5318-23. DOI: <https://doi.org/10.1016/j.radcr.2024.08.010> PMID: 39280732
9. Parlakgumus A, Parlakgumus HA, Ezer A. A rare cause of acute appendicitis: migration of an intrauterine device. *J Coll Physicians Surg Pak* 2017; 27(5): 323-4.
10. Key TC, Kreutner AK. Gastrointestinal complications of modern intrauterine devices. *Obstet Gynecol* 1980; 55(2): 239-44. PMID: 7352087
11. Leh BKI, Ibrahim AK, Bernadette NA, Serge EA, Amos KB, Nahed D, *et al.* Unusual cause of acute appendicitis: bone fragment. *Surg Sci* 2023; 14(3): 221-4. DOI: <https://doi.org/10.4236/ss.2023.143025>