

Pain Relief in Patients with Spinal Metastases Undergoing Spinal Instrumentation

Prof. Salman Yousuf Sharif¹ and Dr. Yousuf Shaikh^{2*}

¹Head of the Department, Department of Neurosurgery, Liaquat National Hospital, Karachi

²Resident, Department of Neurosurgery, Liaquat National Hospital, Karachi

ABSTRACT

Introduction: Spine represents the third most common site of metastasis after lung and liver and is a frequent cause leading to neurosurgical consultation. Affected individuals usually present with symptoms of pain or progressive weakness of bilateral lower extremities. Pain is an important factor to consider as it significantly reduces the quality of life and leads to recumbency. However, increasing age and relative frail nature of patients with metastatic disease makes decision making difficult. As the treatment options for metastatic spine continues to grow, it has now become evident that devising a treatment plan can only be achieved by multidisciplinary team approach. The objective of our study is to assess pre and post-op VAS of these patients following surgical stabilization of metastatic unstable spine.

Methods: A retrospective study was conducted at Department of Neurosurgery, Liaquat National Hospital, Karachi. 50 consecutive patients who underwent spinal stabilization procedures due to instability or intractable pain from a period of June 2017 to June 2018 were included in study. We assessed their pre and post-operative pain using Visual Analog Scale (VAS). The decision to operate was based on the degree of instability either potentially or completely unstable on the basis of Spinal Instability Neoplastic Score (SINS), progressive neurological deficit, severity of pain and survival more than 6 months. Average survival was calculated using Revised Tokuhashi Score.

Results: 50 patients underwent spinal stabilization procedure due to spinal metastasis. Average age of patient was 56.78 ± 10.93 years and a minimum of 6 months follow-up was present in all cases. Mean VAS score for all these patients at baseline was 7.9 ± 1.44 and post-operatively average VAS score at 1 month was 1.8 ± 0.57 . Significant pain control was achieved after the surgery ($p < 0.001$). 2(4%) patients underwent debridement due to infection along with I/V antibiotics and recovered satisfactorily.

Conclusion: All patients showed significant improvement in pain control following surgery with minimal complications.

Keywords: Back pain, Spinal metastases, Pedicle screw fixation.

INTRODUCTION

Spine represents the third most common site of metastasis after lung and liver and is a frequent cause leading to neurosurgical consultation [1, 2]. It can cause a number of sequelae including pain, instability, and neurologic deficit. If left untreated, progressive myelopathy can result in the loss of motor, sensory, and autonomic functions. The five most common malignancies that metastasize to spine include breast, lungs, prostate, kidneys and thyroid with breast being the most common in females and lung in males [3]. Majority of such patients present with gradual onset lower limb weakness or pain localized to the site of vertebral involvement. The purpose of neurosurgical consultation in all these patients is to identify those who will benefit with decompression and stabilization procedures. One of the important features that may facilitate diagnosis is the tendency to spare disc spaces where as infective lesions tend to involve the discs [4]. Among the routes mentioned above, hematogenous spread through Batson's plexus system is the most common pathway for tumor embolization and spinal invasion [5]. In certain circumstances, it is usually the

metastases that become symptomatic which makes necessary a search for primary [6]. A general rule that is being followed is to offer surgery to all those patients whose expected survival is more than 6 months [7]. The goal of surgery is to achieve adequate neural decompression while simultaneously utilizing various internal fixation devices to stabilize the spinal column. As the treatment options for metastatic spine continue to grow, it has now become evident that devising a treatment plan can only be achieved by multidisciplinary team approach. The objective of our study is to assess pre and post-operative pain in patients undergoing spinal instrumentation.

MATERIAL AND METHODS

We retrospectively reviewed 50 consecutive patients who underwent spinal stabilization procedures at Liaquat National Hospital due to instability or intractable pain from a period of June 2017 to June 2018. Spinal Instrumentation means to achieve spine rigidity by surgically fixating it with rods, screws and hooks in a way that it restores its normal height and curvature. We assessed pre and post-operative pain of patients undergoing spinal stabilization which was measured using Visual Analog Scale (VAS). All these patients were referred to neurosurgical clinic by oncologist due to recently diagnosed spinal metastasis and were extensively evaluated preoperatively. CT scan and MRI

*Corresponding Author: Dr. Yousuf Shaikh, Resident, Department of Neurosurgery, Liaquat National Hospital, Karachi;

Email: unknownyou@hotmail.com

Received: October 30, 2019; Accepted: December 01, 2019

contrast of spine was performed in all patients. CT scan chest and abdomen was also performed to assess the systemic distribution of disease and to calculate expected survival. The inclusion criteria was based on the degree of instability either potentially or completely unstable on the basis of Spinal Instability Neoplastic Score (SINS), progressive neurological deficit, severity of pain and survival more than 6 months of either gender and age. Depending upon the degree of instability and patients characteristics like age and co-morbidities, anterior or posterior fusion surgery was planned in a surgeons preferred manner. Patients who had stable spine and survival less than 6 months were not offered surgery and excluded from the study. Patients' survival was calculated using revised Tokuhashi score. Patients with a revised Tokuhashi score of more than 11 (good prognosis) survive an average of 25 months, those with a score of 9-11 (moderate prognosis) survive an average of 17 months, and those with a score of 8 or less (poor prognosis) survive an average of 5 months [8]. The severity of pain both pre and post-operative was calculated using VAS. Post-operative VAS at 1-2 weeks was not considered reliable due to different levels of analgesia required depending upon the severity of pain. Postoperative VAS scoring was done at 1 month after complete healing of wound and 4 weeks of rehabilitation and occupational therapy. It was measured at 4 weeks when all patients were weaned off pain medications.

Patients' demographics and clinical variables were summarized in terms of mean \pm standard deviation for continuous variables and frequencies with percentages for categorical variables. Pre and post-operatively VAS was compared using paired t-test. P-value < 0.05 was taken as statistically significant. Statistical analysis was performed on statistical package SPSS version 22.

RESULTS

50 patients underwent spinal stabilization procedure due to spinal metastasis. Average age of patient was 56.78 ± 10.93 years and all patients were followed for a variable period of 6-18 months. A minimum of 6 months follow-up was present in all cases. The site of metastasis was dorsal in 22(44%) patients, lumbar in 19(38%) patients, cervical in 7(14%) patients, and sacral in 2(4%) patients (Fig. 1). The source of metastasis was identified to be

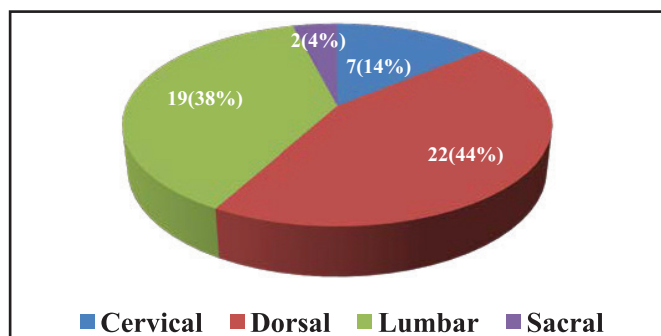


Fig. (1): Site of spinal metastasis.

breast in 13(26%) patients, lung in 11(22%) patients, prostate in 4(8%) patients, renal cell in 5(10%) patients, bladder in 3(6%) patients, liver in 3(6%) patients, gastrointestinal in 2(4%) patients, and thyroid in 2(4%) patients and unidentified in 7(14%) cases.

Mean VAS score for all these patients at baseline was 7.9 ± 1.44 and post-operatively average VAS score at 1 month was 1.8 ± 0.57 . On an average, there was decrease of 6.1 ± 1.50 in post-operative VAS score which indicated that all patients achieved significant pain control following their surgery ($p < 0.001$) (Fig. 2). 2(4%) patients underwent debridement due to infection along with I/V antibiotics and recovered satisfactorily.

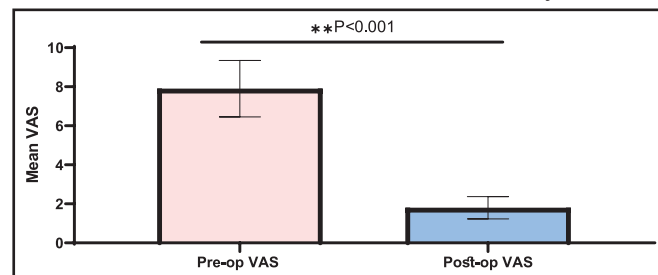


Fig. (2): Pre- and post-operative comparison of VAS score.

Note: Pre-opVAS = pre-operative visual analogue scale score, Post-op VAS = post-operative visual analogue scale score, $**P < 0.001$ = significant at $p < 0.01$.

DISCUSSION

Spinal metastasis is a common entity and requires a multidisciplinary team approach. One of the major aspects in the treatment of such patients is estimating life expectancy. This should be done on the basis of universally accepted criteria. Many such scoring systems have been developed which can help in guiding treatment and selecting patients for surgery. Tomita *et al.* described a system based on 3 factors (primary tumor, visceral and bone metastases). Tokuhashi *et al.* devised a system of 6 parameters, which was later subjected to revision with the addition of Karnofsky score, neurological status and tumor type. Similarly, North *et al.* gave a classification system, which found non breast metastasis, recurrence, multilevel surgery, and paraplegia to be significant factors in prognosis. All these scores provide rough estimation of expected survival. Considering the fact the revised Tokuhashi score takes into consideration the most factors including patient and tumor, it was selected as a mean of survival calculator in our patients.

Majority of patients presented with pain being the most common and usually the first symptom [9]. At this stage a detailed examination followed by staging of the disease is required with simultaneous control of pain. Most of these oncological patients are prescribed morphine for their pain control but occasionally it may not be sufficient and may only provide pain relief in recumbency leading to significant limitation in movement. Localized radiotherapy is an alternate modality to address radiosensitive

painful metastases. There are two ways how radiation therapy can be employed. One is Conventional External Beam Radiation Therapy (cERBT) and the other is Stereotactic Radio Surgery (SRS) with the main difference being cEBRT can be used for spinal cord compression, whereas use of SRS requires a minimum of 2-3mm separation between tumor and neural tissue. Radiosensitive tumors like myeloma, lymphoma may show remarkable response to radiation therapy alone, where as radio resistant tumors can be addressed by SRS. Since SRS does not depend on tumor histology, it is frequently used in radio resistant spinal metastasis combined with surgery to achieve better disease control and improve outcome [10-12].

The type of analgesia used is quite variable and also depends upon the availability of opioids. In our setting routine analgesia consisting of a combination of NSAIDs and paracetamol was used in all patients pre-operatively. Oral formulations of morphine were used if patients did not respond to routine medications. VAS was measured prior to prescription of pain medications pre-operatively. Post-operatively, none of the patients were given morphine and all of them had significant improvement in pain.

The role of surgery is largely to address compression and instability. Clinically, this manifests as increasing severity of pain with some relief on recumbency. In these circumstances, simple laminectomies are not recommended and in fact discouraged as it may make instability worse. Fusion is therefore recommended in such cases. The choice of surgical approach and means to achieve spinal stabilization are vast. These may vary from simple kypholasty/vertebroplasty to extensive open procedures with pedicle screw fixation to minimally invasive techniques. In our patients stability was achieved by posterior laminectomy of the involved vertebra with transpedicular anterior displacement of fractured segments in canal with proximal and distal pedicle screw fixation. With the recent advances in instrumentation techniques, the risks associated with open surgery and blood loss can be minimized by employing minimally invasive techniques. The minimally invasive surgeries can easily achieve the objectives of decompression, stability, and disease control in most cases [13-16].

Our study showed that 2 patients (4%) experienced complications in the form of wound infection with both of them requiring surgical debridement. Two studies utilized percutaneous pedicle screw fixation to address spinal metastases with complication rate of 9% and 17% respectively [17, 18]. In comparison, several retrospective studies have investigated complication rates after open surgical procedures for the treatment of spinal metastases, with complication rates reported between 15 and 47% [19]. The high risk for complications does not only reflect the surgical demand of these procedures but also reflects the fragility of this patient category [20]. Our study had fairly good results.

Spinal metastases require a multidisciplinary team approach in terms of systemic control of disease, pain management and surgical considerations. Pain represents the most important element because it adds considerable suffering to the patient.

CONCLUSION

We conclude that all patients showed significant improvement in pain control following surgery with minimal complications.

ACKNOWLEDGEMENT

None.

CONFLICT OF INTEREST

The authors declare no conflicts of interest.

REFERENCES

1. Kaczmarczyk J, Nowakowski A, Oszkini G, Nazar J. Surgical treatment of neoplasm metastasis to the spine. *Chirurgia Narzadow Ruchu I Ortopedia Polska* 2003; 68(1): 9-11.
2. Boland PJ, Lane JM, Sundaresan N. Metastatic disease of the spine. *Clin Orthop Relat Res* 1982;169: 95-102.
3. Maccauro G, Spinelli MS, Mauro S, Perisano C, Graci C, Rosa MA. Physiopathology of spine metastasis. *Int J Surg Oncol* 2011; 107969: 2011.
4. Chamberlain MC, Sloan A, Vrionis F, Cancer Care Ontario Practice Guidelines Initiative's Neuro-Oncology Disease Site Group. Systematic review of the diagnosis and management of malignant extradural spine cord compression: the Cancer Care Ontario Practice Guidelines Initiative's Neuro-Oncology Disease Site Group. *J Clin Oncol* 2005; 23(30): 7750-1.
5. Loblaw DA, Perry J, Chambers A, Laperriere NJ. Systematic review of the diagnosis and management of malignant extradural spinal cord compression: the Cancer Care Ontario Practice Guidelines Initiative's Neuro-Oncology Disease Site Group. *J Clin Oncol* 2005; 23(9): 2028-37.
6. Hosono N, Yonenobu K, Fuji T, Ebara S, Yamashita K, Ono K. Orthopaedic management of spinal metastases. *Clinical Orthop Relat Res* 1995; 312: 148-59.
7. Katagiri H. Prognostic factors and a scoring system for patients with skeletal metastasis. *J Bone Joint Surg* 2005; 87B: 698-703.
8. Aoude A, Amiot L-P. A comparison of the modified Tokunashi and Tomita scores in determining prognosis for patients afflicted with spinal metastasis. *Can J Surg* 2014; 57(3): 188-19.
9. Prasad D, Schiff D. Malignant spinal-cord compression. *The Lancet Oncol* 2005; 6: 15-24.
10. Baaj AA, Gokaslan ZL. Spine metastasis. *J Neurosurg Spine* 2012; 17: 269.
11. Ryu S, Yoon H, Stessin A, Gutman F, Rosiello A, Davis R. Contemporary treatment with radiosurgery for spine metastasis and spinal cord compression in 2015. *Radiat Oncol J* 2015; 33: 1-11.
12. Sohn S, Chung CK. The role of stereotactic radiosurgery in metastasis to the spine. *J Korean Neurosurg Soc* 2012; 51: 1-7.
13. Arnold PM. Editorial: spine metastasis. *J Neurosurg Spine* 2013; 18: 215-6.
14. Bhatt AD, Schuler JC, Boakye M, Woo SY. Current and emerging concepts in non-invasive and minimally invasive management of spine metastasis. *Cancer Treat Rev* 2013; 39: 142-52.
15. Guarnieri G, Izzo R, Muto M. Current trends in mini-invasive management of spine metastases. *Interventional neuroradiology. J Peritherapeutic Neuroradiol Surg Procedures Relat Neurosci* 2015; 21: 263-72.

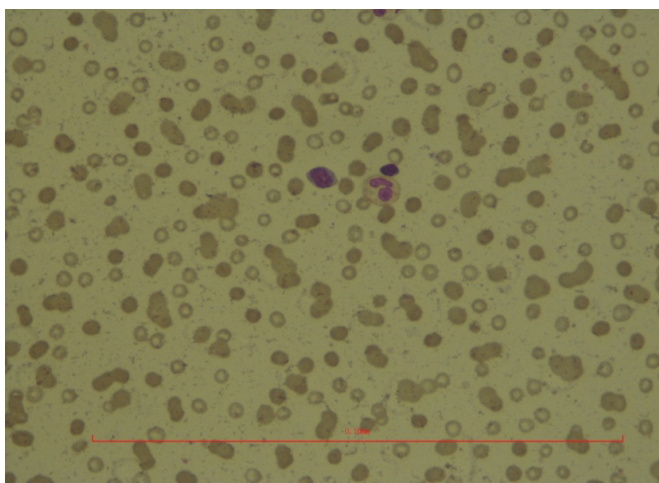
16. Huang TJ, Hsu RW, Li YY, Cheng CC. Minimal access spinal surgery (MASS) in treating thoracic spine metastasis. *Spine* 2006; 31: 1860-63.
17. Moussazadeh N, Rubin D, McLaughlin L, Lis E, Bilsky MH, Laufer I. Short-segment percutaneous pedicle screw fixation with cement augmentation for tumor-induced spinal instability. *Spine J* 2015; 15: 1609-17.
18. Park HY, Lee SH, Park SJ, Kim ES, Lee CS, Eoh W. Minimally invasive option using percutaneous pedicle screw for instability of metastasis involving thoracolumbar and lumbar spine: a case series in a single center. *J Korean Neurosurg Soc* 2015; 57: 100.
19. Dea N, Versteeg A, Fisher C, *et al.* Adverse events in emergency oncological spine surgery: a prospective analysis. *J Neurosurg Spine* 2014; 21: 698-703.
20. Patil CG, Lad SP, Santarelli, Boakye M. National inpatient complications and outcomes after surgery for spinal metastasis from 1993-2002. *Cancer* 2007; 110: 625-30.

QUESTION # 1:

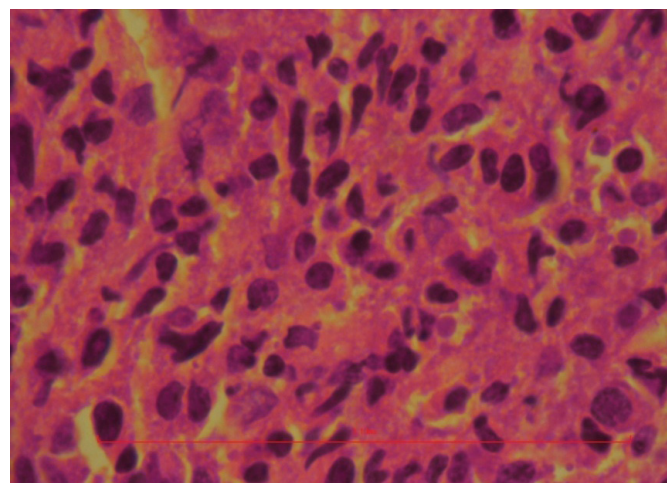
Dr. Sobia Tabassum

60-year-woman presented with fracture of left femur, her Hb is 8.9 gm% and creatinine is 2.5 mg/dl. Her peripheral blood film showing:

And her bone marrow biopsy showed:



And her bone marrow biopsy showed:



What are the high risk chromosomal abnormalities in above condition?

QUESTION #2:

45-year-old male patient came with history of abdominal pain. A triphasic CT abdomen was done.

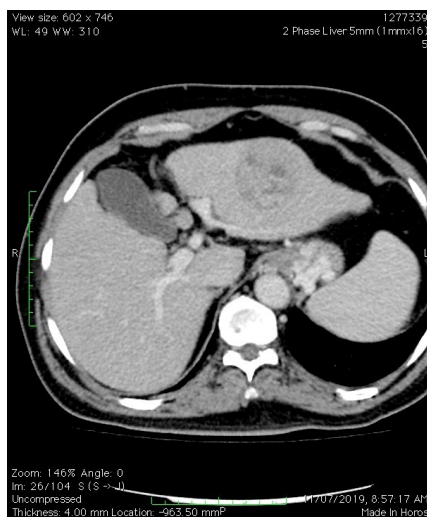


Fig. (1): Venous phase.

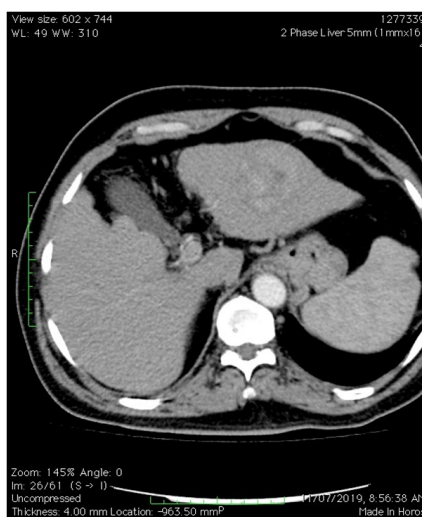


Fig. (2): Arterial phase.

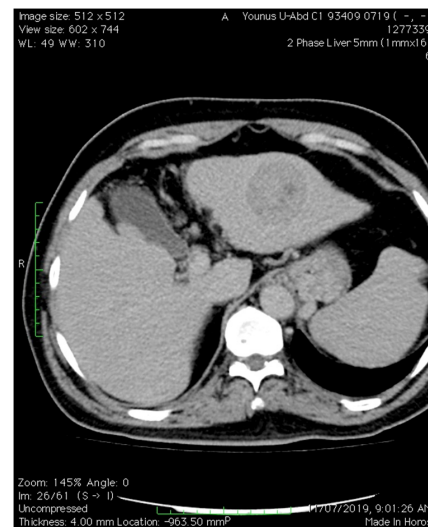


Fig. (3): Delayed phase.

What are the findings in the given images?
What is your diagnosis?